



Enamel Microabrasion for Removal of Decalcification, Dysmineralization, and Surface Texture Defects

Theodore P. Croll, DDS

Private Practice, Doylestown, Pennsylvania; Adjunct Professor of Pediatric Dentistry, Dental School, University of Texas Health Science Center at San Antonio, San Antonio, Texas; Affiliate Professor, Department of Pediatric Dentistry, University of Washington School of Dentistry, Seattle, Washington.

Kevin J. Donly, DDS, MS

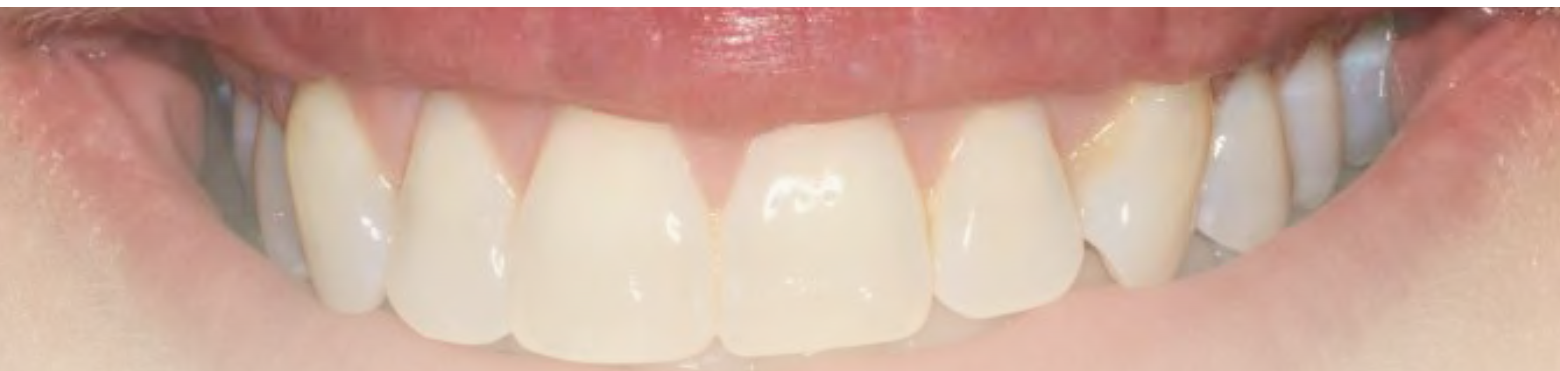Professor and Chair, Department of Developmental Dentistry, Dental School, University of Texas Health Science Center at San Antonio, San Antonio, Texas.

Using a combination of hydrochloric acid erosion and mechanical abrasion with powdered silicon carbide, superficial enamel discoloration and texture defects can be eliminated. Enamel microabrasion was developed in the 1980s and, used alone or in combination with dental bleaching, has proven to be a conservative method of improving tooth appearance. This article offers a 27-year retrospective on a subject who was treated at age 10. It also documents the use of enamel microabrasion for treatment of dysmineralization, decalcification, and an enamel texture abnormality. *Am J Esthet Dent* 2013;3:92–99. doi: 10.11607/ajed.0063

Correspondence to: Dr Theodore P. Croll
708 N Shady Retreat Road, Suite 2, Doylestown, PA 18901.
Email: willipus@comcast.net

©2013 by Quintessence Publishing Co Inc.





In 1984, Robert McCloskey described the work of Walter Kane, who, in the early 1900s, used muriatic (hydrochloric) acid to erode endemic white-and-brown fluorosis discoloration from anterior teeth.¹ McCloskey reported the 44-year results of a 16-year-old girl who was treated by Kane in 1926. The same patient was photographed in 1986, as a 76-year-old, and these photographs showed that there was still a stark difference in the appearance of the anterior teeth compared to the untreated premolars and molars.²

Using a combination of hydrochloric acid and laboratory pumice, Croll discovered that superficial enamel staining could be eliminated by erosion and abrasion in concert. Croll and Cavanaugh termed such treatment *enamel microabrasion*.^{3,4} Analogous to dermabrasion of skin surfaces, enamel microabrasion aims to remove intrinsic yet superficial enamel discoloration and texture defects without the need for restorative masking or artificial replacements such as resin-based composite or bonded porcelain veneers. Successful microabrasion removes an insignificant and unrecognizable amount of surface enamel along with the discolored or unesthetically textured tissue. Enamel microabrasion can often be combined with dental bleaching for optimal esthetic results.⁵⁻⁹

Enamel microabrasion has become a routine clinical procedure in dentistry, and commercial microabrasion products (eg, PREMA, Premier Dental; Opalustre, Ultradent) are available to facilitate treatment. These products contain a low concentration of hydrochloric acid and silicon carbide abrasive powder in a silica gel for rotary application. Research has shown that use of these products creates a lustrous enamel surface that is more resistant to acid challenge and plaque accumulation than untreated surfaces.^{10,11} Polarized light microscopy and scanning electron microscopy studies have revealed that microabrasion results in an enamel surface with a superficial layer of compacted, aprismatic mineral that provides a glass-like clinical appearance.^{12,13} Combining mechanical abrasion and chemical erosion inspired the terms *abrasion effect*¹³ and the resulting *enamel glaze*.

This article demonstrates the enamel microabrasion treatment of three patients. One patient had enamel dysmineralization, another decalcification, and the third congenital enamel texture malformation. A fourth case is documented with 27-year results.

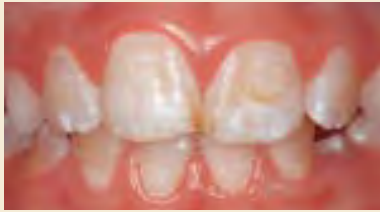

Fig 1a Ten-year-old patient with white-and-brown idiopathic enamel dysmineralization.



Fig 1b Microabrasion compound applied with the rubber applicator tip.



Fig 1c Side flutes were also used for application.

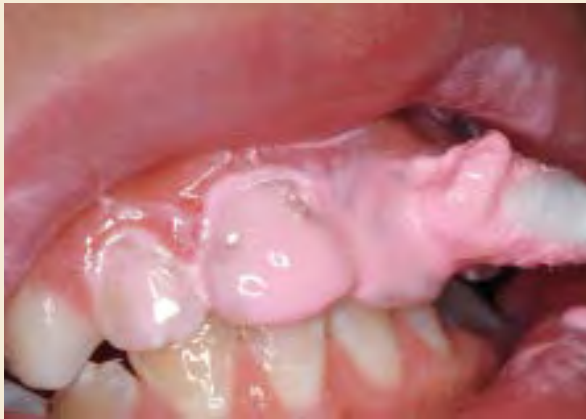

Fig 1d Application of fluoride/calcium phosphate gel.

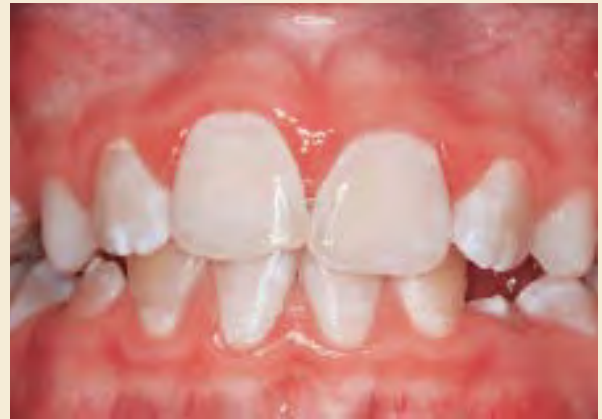

Fig 1e Immediate posttreatment view.

CASE REPORTS

Case 1

A 10-year-old boy presented with white-and-brown idiopathic dysmineralization, chiefly of the labial surfaces of the maxillary central incisors (Fig 1a). Fluoride was not considered to be the likely cause of the discoloration because there were no markings on the permanent first molars and because the parent could not identify any possible sources of excess fluoride. Some white dysmineralization spots and streaks were seen on other anterior

teeth, but these were of no concern to the parent or patient. Enamel microabrasion (PREMA) was performed as follows to remove the discoloration of the central incisors:

1. The patient was fitted with protective eyeglasses. Rubber dam was applied in the usual manner, and a dollop of the compound was syringed onto the labial surface of each incisor.
2. The rubber tip applicator was used at a very slow speed to rub the enamel abrasion compound onto the enamel surfaces (Fig 1b). Care was taken

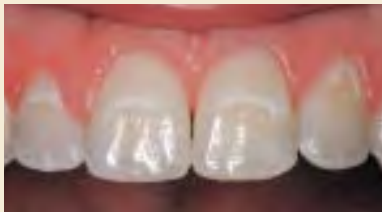

Fig 2a Decalcification due to inadequate oral hygiene during orthodontic treatment.

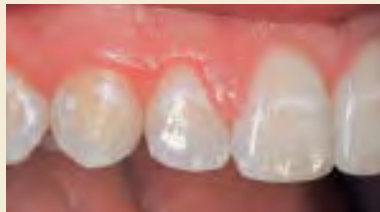

Fig 2b Right lateral view of the decalcification.

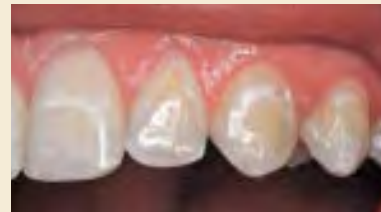

Fig 2c Left lateral view. Note the caries lesion on the canine.

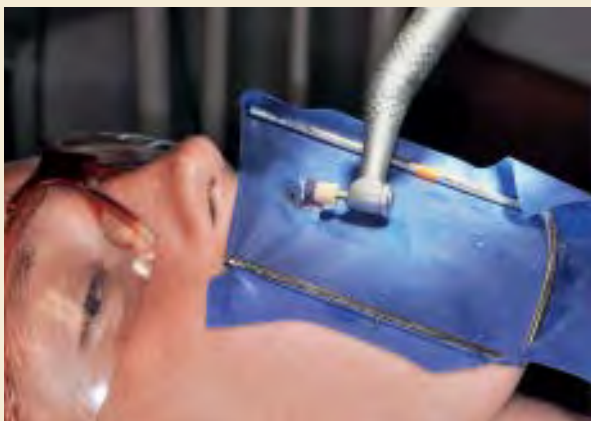

Fig 2d Operative field and eye protection during enamel microabrasion.

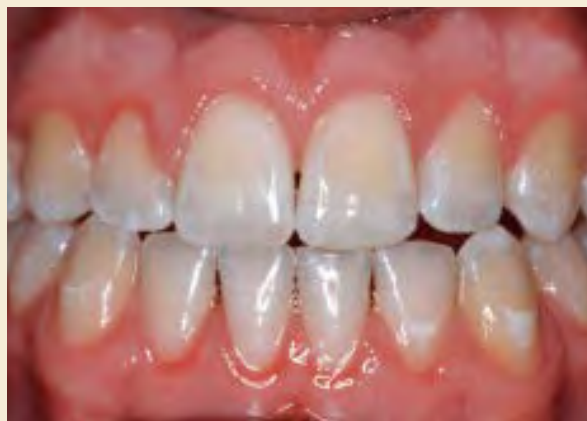

Fig 2e Three-month follow-up view after enamel microabrasion and restoration of the left canine.

- to avoid splattering of the material. The compound was applied in 10- to 15-second intervals with intermittent water rinsing to check the results. The side flutes of the applicator were also used to apply the compound (Fig 1c).
3. After six applications (approximately 60 to 90 seconds of contact time), the enamel discoloration had been removed. The teeth were rinsed thoroughly with water spray.
 4. Fluoride gel containing amorphous calcium phosphate (Enamel Pro Gel, Premier Dental) was applied to the treated tooth surfaces and left in place for 3 minutes (Fig 1d).

5. Immediately after treatment, the central incisors showed an improved appearance (Fig 1e). The parents made the decision to delay carbamide peroxide custom-tray bleaching until after loss of the primary teeth and completion of orthodontic treatment.

Case 2

A 16-year-old boy presented with white decalcification markings in the gingival half of his maxillary anterior teeth. These markings were related to inadequate oral hygiene during orthodontic

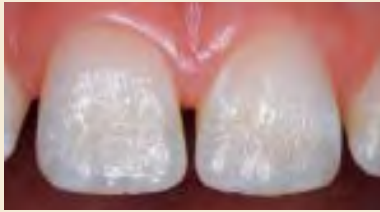

Fig 3a Eight-year-old patient with pitting-type amelogenesis imperfecta.

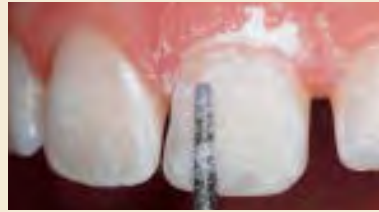

Fig 3b Low-speed diamond bur used to initiate enamel microreduction.



Fig 3c Microabrasion slurry applied with rubber cup/brush assembly.

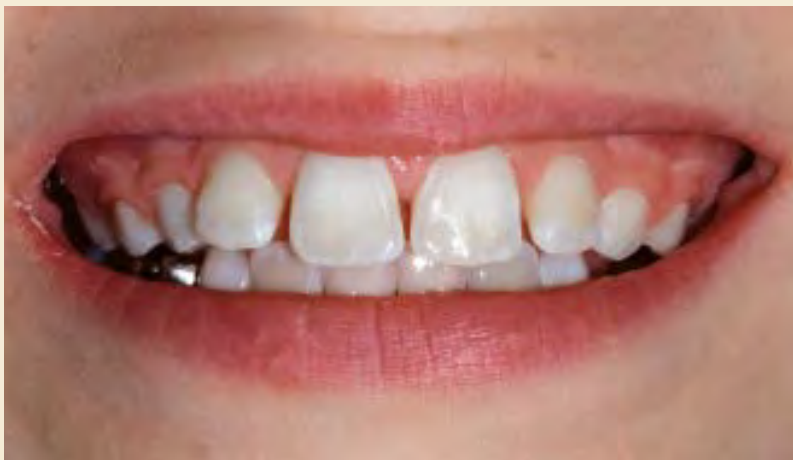

Fig 3d Three months after enamel microabrasion, the enamel texture appears normal.

therapy (Figs 2a to 2c).¹⁴ There was a caries lesion associated with the decalcification on the maxillary left canine. The maxillary premolars also showed facial decalcification spots. A small shear fracture was noted on the maxillary left first premolar, which may have occurred during orthodontic bracket removal (Fig 2c). That fractured region was smoothed with a fine-tipped diamond bur. White decalcification areas were also seen on some mandibular teeth, but none were noticeable when the patient spoke or smiled, and none showed associated caries.

The six maxillary teeth were treated using enamel microabrasion as described for the previous case (Fig 2d).

Following microabrasion, the left canine was restored with a bonded resin-based composite restoration in the usual manner. The patient and parent were not immediately interested in tooth whitening but mentioned that they might be interested in the future. Figure 2e shows the 3-month results.

Case 3

An 8-year-old girl demonstrated a pitting type of amelogenesis imperfecta (Fig 3a). The labial surfaces of the maxillary incisors had multiple round notches that did not penetrate deeply into the surface. The maxillary central incisors were more significantly affected

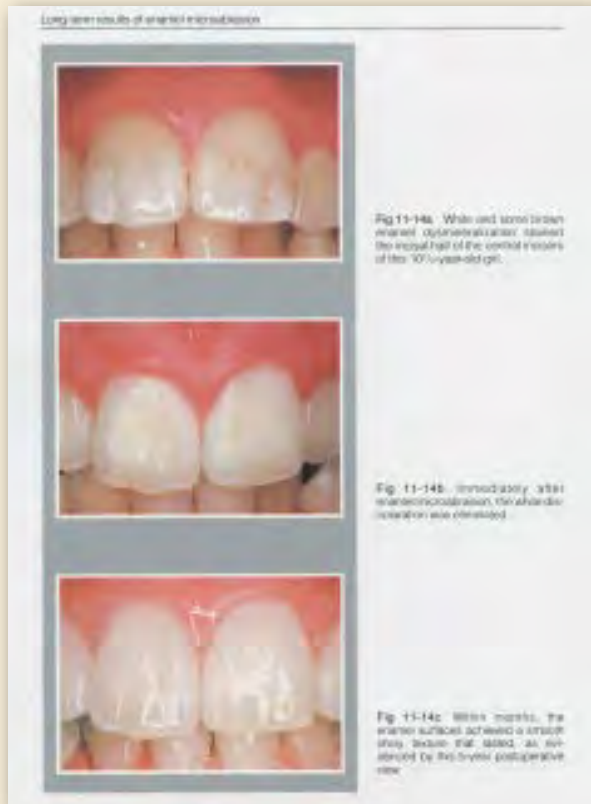


Fig 4a (left) Documented treatment of a 10-year-old patient in 1985. Reprinted with permission from Croll.¹⁷

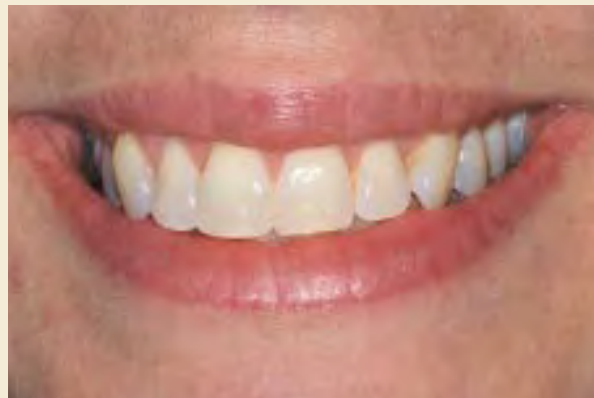

Fig 4b Smile view 27 years after microabrasion and 2 years after bleaching.

than the lateral incisors. Although the appearance of these incisors could have been substantially improved with bonded resin-based composite restorations, it was decided that the enamel defects were superficial enough to be eliminated rather than covered up.¹⁵

To hasten the procedure, a good portion of the enamel removal was achieved with a low-speed diamond bur prior to placement of rubber dam (Fig 3b).¹⁶ Enamel microabrasion was performed using Opalustre Enamel Microabrasion Slurry in the same manner as described for the other cases. A rubber cup with internal brush bristles (Ultradent) was used to apply the slurry to all four incisors (Fig 3c). Three

months later, the incisors showed a much-improved appearance (Fig 3d).

Case 4

In 1985, a 10-year-old girl presented with white-and-brown idiopathic enamel dysmineralization discoloration of her maxillary central incisors. Enamel microabrasion was completed, and the treatment was documented in a textbook written by the first author (Fig 4a).¹⁷ Twenty-five years after treatment, the patient underwent custom-tray carbamide peroxide tooth bleaching. Figure 4b shows the patient's smile 2 years after bleaching and 27 years after enamel microabrasion.



DISCUSSION AND CONCLUSIONS

After more than a quarter-century of experience and research regarding enamel microabrasion, several principles regarding enamel microabrasion can be stated:

- Enamel microabrasion preserves more tooth structure than treatments such as porcelain or resin-based composite veneering. It is also significantly less expensive.
 - The results of enamel microabrasion are permanent. In contrast, masking with artificial material will eventually require additional intervention.
 - The glass-like surface resulting from the combination of abrasion and erosion better resists acid dissolution and bacteria accumulation than untreated surfaces.
 - Many intrinsic enamel surface defects are superficial enough to be eliminated without replacing the lost enamel. Slight and moderate white-and-brown fluorosis discoloration are good examples of this type of dysmineralization. Teeth with deeper enamel defects should be treated with traditional restorative methods. When the clinician is unsure which method is best suited for a given case, there is nothing to lose except clinical time by first attempting microabrasion.
 - White enamel dysmineralization does not always need to be completely removed during the microabrasion procedure. Even though residual white streaks or spots may be visible when the tooth is completely dry, such defects are often camouflaged when the tooth surface is saturated with body-temperature saliva. Thus, the appearance of microabraded teeth should be assessed when wet with saliva.
- Although mechanical stripping of enamel with burs or disks can also remove superficial defects, this technique lacks control and will not provide the enamel glaze. However, time can be saved by beginning with mechanical enamel microreduction (diamond burs or disks), followed by completion of treatment with rotary application of the microabrasion compound.
 - In many cases, the most striking results occur when enamel microabrasion is combined with dental bleaching. Microabrasion removes unsightly superficial defects and creates a lustrous smooth surface, while tooth bleaching whitens the deep intrinsic yellow coloration of dentin. Microabraded teeth that are also bleached provide a brighter, whiter, and healthier appearance.

ACKNOWLEDGMENTS

The first author (TPC) had a former financial interest in PREMA and Opalustre. Neither author has a current financial interest in any products mentioned in this article.



REFERENCES

1. McCloskey RJ. A technique for removal of fluorosis stains. *J Am Dent Assoc* 1984;109:63–64.
2. Croll TP. A case of enamel color modification: 60-year results. *Quintessence Int* 1987;18:493–495.
3. Croll TP, Cavanaugh RR. Enamel color modification by controlled hydrochloric acid-pumice abrasion. I. Technique and examples. *Quintessence Int* 1986;17:81–87.
4. Croll TP, Cavanaugh RR. Hydrochloric acid-pumice enamel surface abrasion for color modification: Results after six months. *Quintessence Int* 1986;17:335–341.
5. Haywood VB, Heymann HO. Nightguard vital bleaching. *Quintessence Int* 1989;20:173–176.
6. Cvitko E, Swift EJ, Denehy GE. Improved esthetics with a combined bleaching technique: A case report. *Quintessence Int* 1992;23:91–93.
7. Croll TP. Enamel microabrasion followed by dental bleaching: Case reports. *Quintessence Int* 1992;23:317–321.
8. Killian CM. Conservative color improvement for teeth with fluorosis-type stain. *J Am Dent Assoc* 1993;124:72–74.
9. Croll TP. Aesthetic correction for teeth with fluorosis and fluorosis-like enamel dysmineralization. *J Esthetic Dent* 1998;10:21–29.
10. Segura A, Donly KJ, Wefel JS. The effects of microabrasion on demineralization inhibition of enamel surfaces. *Quintessence Int* 1997;28:463–466.
11. Segura A, Donly KJ, Wefel JS, Drake D. Effect of enamel microabrasion on bacterial colonization. *Am J Dent* 1997;10:272–274.
12. Berg JH, Donly KJ. The enamel surface and enamel microabrasion. In: Croll TP (ed). *Enamel Microabrasion*. Chicago: Quintessence, 1991:55–60.
13. Donly KJ, O'Neill M, Croll TP. Enamel microabrasion: A microscopic evaluation of the "abrasion effect." *Quintessence Int* 1992;23:175–179.
14. Croll TP, Bullock GA. Enamel microabrasion for removal of smooth surface decalcification lesions. *J Clin Orthod* 1994;28:365–370.
15. Killian CM, Croll TP. Enamel microabrasion to improve enamel surface texture. *J Esthet Dent* 1990;2:125–128.
16. Croll TP. Hastening the enamel microabrasion procedure. *J Am Dent Assoc* 1993;124:87–90.
17. Croll TP. Long-term results of enamel microabrasion. In: *Enamel Microabrasion*. Chicago: Quintessence, 1991:96.